

⁶⁸Ga-PSMA has a high detection rate of prostate cancer recurrence outside the prostatic fossa in patients being considered for salvage radiation treatment

Pim J. van Leeuwen^{*,†}, Phillip Stricker^{*,†}, George Hruby^{‡,§,¶}, Andrew Kneebone^{‡,§,¶}, Francis Ting^{*,†}, Ben Thompson[†], Quoc Nguyen[†], Bao Ho^{**} and Louise Emmett^{*,††}

^{*}St Vincent's Prostate Cancer Centre, St Vincent's Clinic, Sydney, NSW, [†]Australian Prostate Cancer Research Centre – New South Wales, Garvan Institute of Medical Research/Kinghorn Cancer Centre, Sydney, NSW, [‡]Radiation Oncology Department, Northern Sydney Cancer Centre, Royal North Shore Hospital, St Leonards, NSW, [§]University of Sydney, Sydney, NSW, [¶]Northern Clinical School, University of Sydney, St Leonards, NSW, ^{**}Department of Diagnostic Imaging, St Vincent's Public Hospital, Sydney, NSW, and ^{††}University of New South Wales, Sydney, NSW, Australia

Objectives

To examine the detection rates of ⁶⁸Ga-PSMA-positron emission tomography (PET)/computed tomography (CT) in patients with biochemical recurrence (BCR) after radical prostatectomy (RP), and also the impact on their management.

Materials and Methods

A total of 300 consecutive patients with prostate cancer (PCa) who underwent ⁶⁸Ga-PSMA-PET/CT between February and July 2015 were prospectively included in the Prostate Cancer Imaging (ProCan-I) database. For the present analysis, we included patients with BCR (prostate-specific antigen [PSA] level ≥ 0.05 and < 1.0 ng/mL) after RP, who were being considered for salvage radiation therapy (RT) according to the Faculty of Radiation Oncology Genito-Urinary Group (FROGG) guidelines. Two readers assessed each ⁶⁸Ga-PSMA-PET/CT, and all positive lesions were assigned to an anatomical location. For each patient, the clinical and pathological features were recorded, their association with pathological ⁶⁸Ga-PSMA uptake was investigated, and detection rates were determined according to PSA level.

Results

A total of 70 patients were included, and 53 positive ⁶⁸Ga-PSMA lesions were detected in 38 (54%) patients. Among

patients with PSA levels 0.05–0.09 ng/mL, 8% were definitely positive; the corresponding percentages for the other PSA ranges were as follows: PSA 0.1–0.19 ng/mL, 23%; PSA 0.2–0.29 ng/mL, 58%; PSA 0.3–0.49 ng/mL, 36%; and PSA 0.5–0.99 ng/mL, 57%. Eighteen of 70 patients (27%) had pathological ⁶⁸Ga-PSMA uptake in the prostatic fossa, 11 (14.3%) in the pelvic nodes, and five (4.3%) in both the fossa and pelvic lymph nodes. Finally, there was uptake outside the pelvis with or without a lesion in the fossa or pelvic lymph nodes in four cases (8.6%). As a result of the ⁶⁸Ga-PSMA findings there was a major management change in 20 (28.6%) patients.

Conclusions

⁶⁸Ga-PSMA appears to be useful for re-staging of PCa in patients with rising PSA levels who are being considered for salvage RT even at PSA levels < 0.5 ng/mL. These results underline the need for further prospective trials to evaluate the changes in RT volume or management attributable to ⁶⁸Ga-PSMA findings.

Keywords

⁶⁸Ga-PSMA, PET/CT, prostate cancer, radical prostatectomy, biochemical progression, salvage radiation treatment

Introduction

Radical prostatectomy (RP) is the most widely used treatment for patients with localized prostate cancer (PCa) [1]. After RP, patients are monitored through serial PSA measurements.

A persistent or rising PSA level after RP suggests recurrent PCa, which is experienced by 20–30% of patients after RP [2]. Conventional imaging such as TRUS, MRI, CT, positron emission tomography (PET), bone scan and ¹⁸F-Fluoromethylcholine PET/CT, are neither sensitive nor

specific enough to detect PCa at an early enough stage where salvage radiation therapy (RT) might still be curative [3–5].

Salvage RT to the prostatic fossa is the only potentially curative treatment option for patients with biochemical recurrence (BCR) after RP [6]. In the salvage setting, a dose of at least 64–68 Gy to the prostatic fossa at the lowest possible PSA level (preferably <0.5 ng/mL) is recommended [6–9]. Overall, the 6-year progression-free survival rate in patients undergoing salvage RT is 32%, varying from 48% to 18% in those with a pre-RT PSA level of <0.5 ng/mL and >1.5 ng/mL, respectively [10]. This indicates that, on the one hand, patients with low-volume recurrent PCa benefit the most from salvage RT and, on the other, that there is a substantial number of patients who do not have a durable response after salvage RT [11]. Currently, neither a rising PSA level nor its combination with other adverse pathological features give specific information concerning disease location (i.e. local vs regional vs distant) [12,13]. Because salvage RT is only clinically useful in patients with local disease (disease confined to the prostatic fossa), patients with tumour spread beyond the prostatic fossa should ideally be excluded when selecting patients for prostatic fossa salvage RT. Alternatively, if regional disease is detected (in the absence of distant disease), then the salvage RT volume might be enlarged to include the pelvic nodes in addition to or instead of the prostatic fossa.

Recent data on the novel PET tracer agent Glu-NH-CO-NH-Lys-(Ahx)-[^{68}Ga (HBED-CC)](PSMA) have been shown to have promising sensitivity and specificity for the detection of PCa in patients with early BCR [14–16]. This new PET tracer relies on the overexpression of prostate-specific membrane antigen (PSMA), a transmembrane folate hydrolase, on the surface of PCa cells. This overexpression has been demonstrated both locally and in regional or metastatic lesions within lymph nodes, soft tissue and bone [17]; therefore, imaging with radiolabelled ^{68}Ga -PSMA has the potential to detect lymph node or local recurrence and/or to exclude distant metastases. Of particular clinical relevance, this includes patients with PSA values in the range of those that are exhibited by patients optimally selected for salvage RT [16].

^{68}Ga -PSMA PET/CT has recently been introduced into Australian clinical practice. The aim of the present study was to evaluate the influence of ^{68}Ga -PSMA PET/CT on the intent and planning of salvage RT for BCR after RP. This should, in turn, provide clinical guidance for the use of ^{68}Ga -PSMA PET/CT for a rising PSA level after RP, and direct future clinical trials.

Materials and Methods

Between February and July 2015, ^{68}Ga -PSMA PET/CT was undertaken in 300 consecutive patients at the department of

diagnostic imaging, St Vincent's Hospital, Sydney. All patients were consented for inclusion in the Prostate Cancer Imaging database (ProCan-I). The ProCan-I has the aim to prospectively collect clinical and imaging information on patients requiring a PSMA PET scan for their PCa and to determine how the results of imaging influences the clinical management of patients with PCa. The trial was approved by the institutional Human Research and Ethics Committee.

Patient Population

Men who had undergone RP and were diagnosed with BCR (PSA ≥ 0.05 and <1.0 ng/mL) and were being considered for salvage RT were selected for the present study. No patients had evidence of local/regional recurrence or metastatic disease on conventional clinical evaluation. In all patients, conventional clinical evaluation included a diagnostic contrast-enhanced CT scan abdomen pelvis, reconstructed by standard CT methods, and separately interpreted by the nuclear medicine physicians for the purpose of this study. Patients previously treated with RT or patients on any systemic treatment were excluded. Data on age, previous therapy, time since RP, initial pathology (including T stage and Gleason score), PSA at the time of ^{68}Ga -PSMA-PET/CT and previous imaging were collected at enrolment.

Imaging Protocol

The PSMA was produced on site according to a Good Laboratory Practices-compliant procedure using a TRASIS[®] automated radiopharmacy cassette with radiopharmacy quality control undertaken using an HPLC method.

All PET/CT imaging was undertaken using a Phillips[®] Ingenuity TOF-PET/64-slice CT scanner. For the PSMA PET/CT, a non-contrast-enhanced CT scan was performed 45 min after tracer injection using the following CT parameters: slice thickness 2 mm, soft-tissue reconstruction kernel, 120 keV and 50 mAs; pitch of 0.828; field of view, 600 mm; and a 512 matrix. Immediately after CT scanning, a whole-body PET scan was acquired for 2 min per bed position. The emission data were corrected for randoms, scatter and decay using a Phillips[®] Body-dynamic.xml and Body.xml reconstruction protocol (Phillips, Eindhoven, The Netherlands). All images were viewed and reported using a Phillips[®] Fusion Viewer.

Image Analysis

The ^{68}Ga -PSMA PET/CT images were independently interpreted by two experienced nuclear medicine physicians. Cases of conflicting outcomes were resolved by consensus between the physicians. Data for all ^{68}Ga -PSMA scans were analysed visually and quantitatively. Visual analysis included

a four-point certainty scoring scale (definitely negative, equivocal probably negative, equivocal probably positive, definitely positive), as well as anatomical site and size of lesions. Quantitative analysis was undertaken using an automated maximum standardized uptake value (SUVmax). All equivocal probably positive and definitely positive lesions were assigned to their respective anatomical location (Appendix 1). All positive lymph nodes were measured in the short axis.

Follow-Up and Patient Management

Two experienced radiation oncologists were asked to report on the management plan for each patient before and after their ^{68}Ga -PSMA scan. Before the ^{68}Ga -PSMA PET/CT, all patients were being considered for salvage RT to the prostate fossa according to the Faculty of Radiation Oncology Genito-Urinary Group (FROGG) consensus guideline, i.e. a dose of 64–68 Gy with the treatment fields to the prostatic fossa defined in detail by Sidhom et al. [6]. Changes in management that were attributable to the ^{68}Ga -PSMA results were classified as follows: none, moderate (change in delivery dose, site or volume of the salvage RT) or major (change of selected treatment). Histopathological results for correlation were collected when available.

Statistical Analysis

A positive ^{68}Ga -PSMA scan was defined as an equivocal probably positive or definitely positive interpretation. A McNemar test was used to analyse scan positivity at different PSA intervals (0–0.09, 0.1–0.19, 0.2–0.29, 0.3–0.49 and 0.5–0.99 ng/mL). For continuous variables normality of distribution was verified using a Kolmogorov–Smirnov test. Because variables had no normal distribution, non-parametric tests were used. The Mann–Whitney *U*-test was used to determine the significance of possible associations. Pearson's correlation and binary logistic regression analyses were used to identify determinants for differences between the patients with a positive scan and those with a negative scan considering pT stage, pLN stage, Gleason score, PSA level at the time of ^{68}Ga -PSMA scan, PSA before surgery and time (months) after RP. *P* values <0.05 were considered to indicate statistical significance. Statistical analysis was carried out with IBM SPSS Statistics V21.0.

Results

Patients

A total of 70 patients met the inclusion criteria and were included in the present study. Patient characteristics are shown in Table 1. The median (interquartile range [IQR]) PSA was 0.2 (0.12–0.32) ng/mL at the time of the ^{68}Ga -PSMA PET/CT.

Table 1 Patient population characteristics.

No. of men	70
Variable at RP	
Median (IQR) age, years	62 (57–67)
Median (IQR) PSA, ng/mL	7.3 (5.2–10.1)
Tumour stage, <i>n</i> (%)	
T2	15 (21.4)
T3a	41 (58.6)
T3b	14 (20.0)
Extracapsular extension, <i>n</i> (%)	53 (75.7)
Semical vesical invasion, <i>n</i> (%)	14 (20.0)
Positive surgical margins, <i>n</i> (%)	21 (30%)
Lymph node stage, <i>n</i> (%)	
N0	38 (54.3)
N1	5 (7.1)
NX	27 (38.6)
Gleason score, <i>n</i> (%)	
Gleason 7	46 (65.7)
Gleason 8–10	24 (34.3)
Variable at PSMA scan	
Median (IQR) age, years	67 (60–71)
Median (IQR) PSA, ng/mL	0.2 (0.12–0.32)
Median (IQR) months after RP	38 (14–69)

IQR, interquartile range; PSMA, prostate-specific membrane antigen; RP, radical prostatectomy.

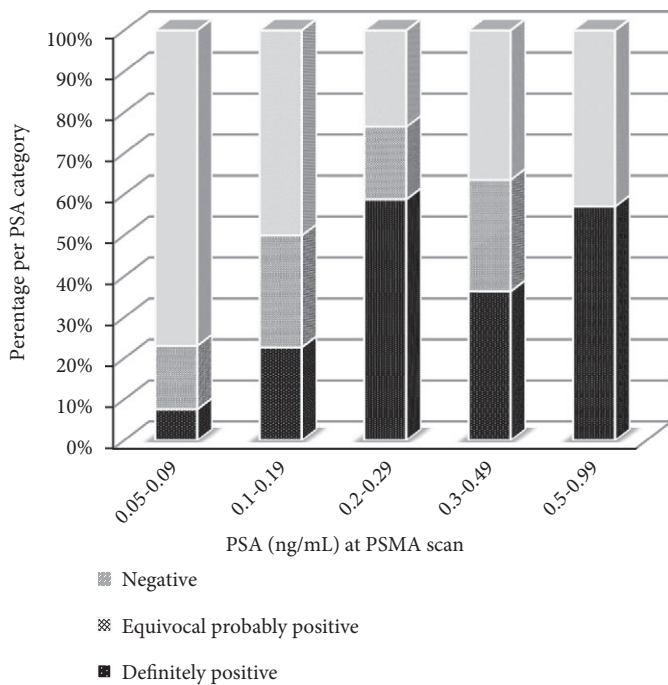
^{68}Ga -PSMA PET/CT Results

Of the 70 patients, 38 (54.3%) had pathological ^{68}Ga -PSMA uptake, and their median (IQR) PSA was 0.21 (0.15–0.32) ng/mL. In the 24 patients reported as having a 'definitely' positive lesion, the median PSA was 0.26 ng/mL compared with 0.18 ng/mL among the equivocal probably positive lesions in 14 patients (*P* = 0.034). The percentages of patients with equivocal probably or definitely positive ^{68}Ga -PSMA per PSA category are shown in Fig. 1. The percentages of patients who were definitely positive, grouped according to PSA level, are as follows: for PSA 0.05–0.09 ng/mL, 8%; for PSA 0.1–0.19 ng/mL, 23%; for PSA 0.2–0.29 ng/mL, 58%; for PSA 0.3–0.49 ng/mL, 36%; and for PSA 0.5–0.99 ng/mL, 57%.

The total number of lesions detected was 53. The actual numbers and median quantitative SUVmax values per PSA category are shown in Table 2. A significant number of patients had more than one lesion identified on ^{68}Ga -PSMA, which increased as PSA level rose. In 25 patients (65.8%) one positive lesion was detected, in 10 patients (26.3%) two positive lesions and in three patients (7.9%) three positive lesions were detected.

While the percentages in Fig. 1 show a high detection rate at very low PSA levels (50% equivocal probably or definitely positive among men with PSA 0.1–0.19 ng/mL), as would be expected, the data also show reduced levels of certainty with lower-volume disease. This was shown both quantitatively on visual assessment (Figs 1 and 2), and with lesion intensity (Table 2). An example of a relatively common observation is shown in Fig. 2: a ^{68}Ga -PSMA PET/CT in a patient with

Fig. 1 Percentage of ⁶⁸Ga-PSMA-positive patients, ranked by ascending PSA level.



rising PSA level after RP at two points in time, with a negative result at PSA 0.15 ng/mL and a positive result at PSA 0.27 ng/mL. The median lesion intensity (SUVmax) of all positive lesions was 3.5. The median SUVmax among all 'definitely' positive lesions was 4.5, and the median SUVmax in all equivocal probably lesions was 3.0 ($P < 0.05$). The median (range) size of a positive lymph node was 5 (3–8) mm (short axis).

Histopathological confirmation was provided in only three patients (7.9%) with positive findings on ⁶⁸Ga-PSMA. Each ⁶⁸Ga-PSMA-positive lesion was confirmed to be a true-positive.

Anatomical Locations of ⁶⁸Ga-PSMA-Positive Pathological Lesions

Of the 70 patients, 18 (27%) had pathological ⁶⁸Ga-PSMA uptake in the prostatic fossa, 11 (14.3%) showed abnormal

uptake in the pelvic lymph nodes, five (4.3%) in the fossa and pelvic lymph nodes, and four (8.6%) had abnormal uptake outside the pelvis with ($n = 2$) or without ($n = 2$) a positive lesion in the prostatic fossa or pelvic nodes. Figure 3 shows the distribution of the 53 ⁶⁸Ga-PSMA-detected lesions in these 38 patients. The numbers in this figure represent the percentage of patients with at least one positive lesion in any given region. The target field for pelvic RT is schematically displayed in Fig. 3 by the dotted contour. Of the 53 positive lesions, four lesions (5.3%) were detected in the prostate bed and 21 (37.5%) were detected in the seminal vesicles. Regionally, 24 lesions (48.2%) were identified in the pelvic lymph nodes. Distantly, two para-aortic lymph nodes (3.5%) and two positive bone lesions (5.3%) were detected (distant disease).

Analysis of Risk Factors

Multivariate analysis was performed for the association of clinical variables with a pathological uptake on ⁶⁸Ga-PSMA; however, no statistically significant association was determined (Table 3). No risk factors could be identified for the presence of positive lymph nodes outside the prostatic fossa (Table 3).

Management Impact

Site of disease recurrence had an important impact on management options. There were 28 positive lesions detected in 20 of 70 patients (28.6%) that were located in either regional lymph nodes or bones that would not have been included in a conventional salvage RT field to the prostatic fossa. After imaging and, accounting for the fact that all patients were considered for salvage RT before the scan, there was no impact on management in 50/70 patients (71.4%). These 50 patients were all either ⁶⁸Ga-PSMA-negative or -positive in the prostatic fossa alone.

Furthermore, the 18 patients (25.7%) with ⁶⁸Ga-PSMA-positive disease within the prostatic fossa (prostate bed or the seminal vesicles) might have been considered as optimum candidates for salvage RT to the prostatic fossa by their treating radiation oncologists. Consideration might also have

Table 2 Number of positive ⁶⁸Ga-PSMA lesions and maximum standardized uptake value per PSA category.

PSA ng/mL at PSMA	Patients, <i>n</i>	Lesions, <i>n</i>	Equivocal probably positive, <i>n</i> (%)	SUVmax, median	Definitely positive, <i>n</i> (%)	SUVmax, median
0.05–0.09	13	4	3 (75)	3.0	1 (25)	4.5
0.1–0.19	22	16	12 (75)	3.2	4 (25)	5.0
0.2–0.29	17	17	6 (35)	2.9	11 (65)	5.0
0.3–0.49	11	9	5 (56)	3.0	4 (44)	4.1
0.5–0.99	7	7	2 (29)	3.1	5 (71)	4.9

PSMA, prostate-specific membrane antigen; SUVmax, maximum standardized uptake value.

Fig. 2 Example of a ⁶⁸Ga-PSMA PET/CT scan in a patient with a rising PSA level after radical prostatectomy at two timepoints: at PSA 0.15 ng/mL (upper part) and at PSA 0.27 ng/mL (lower part), with a negative and positive scan result, respectively.

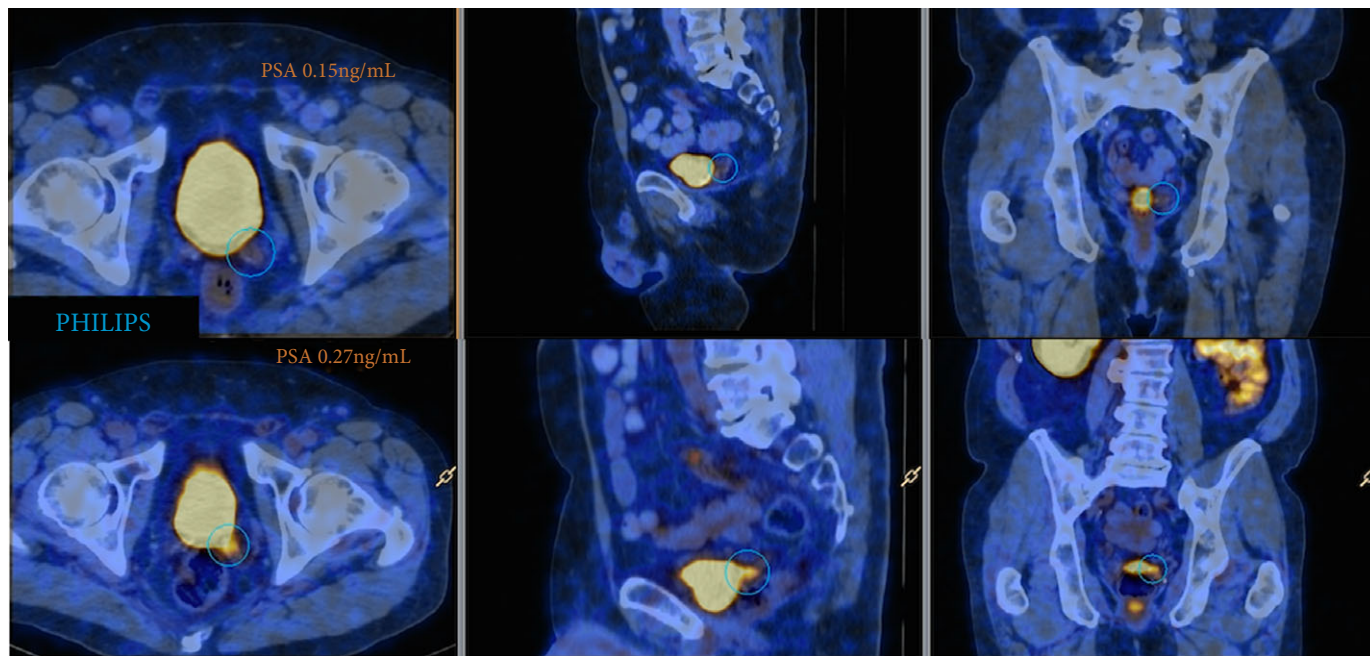


Fig. 3 Distribution of the 53 positive ⁶⁸Ga-PSMA lesions in 38 patients. Numbers represent the percentage of patients with at least one positive lesion in that region. AO, aorta; IVC, inferior vena cava; PS, presacral region; RIA, right internal iliac artery; LIA, left internal iliac artery; REA, right external iliac artery; LEA, left external iliac artery; ROB, right obturator region; LOB, left obturator region; PR, prostate and seminal vesical bed and pararectal region.

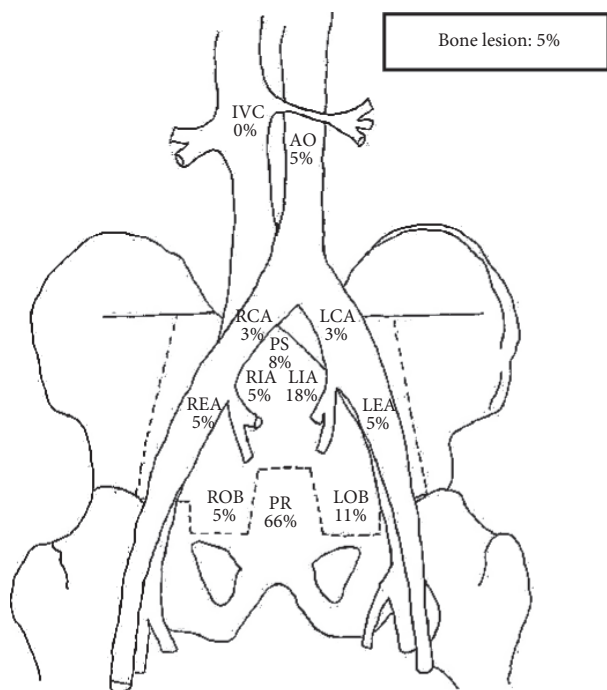


Table 3 Association clinical parameters with positive ⁶⁸Ga-PSMA lesions (outside prostatic fossa).

Variable	Positive lesion all locations		Positive lesion outside prostatic fossa	
	OR	P	OR	P
PSA RP	2.84	0.46	0.69	0.79
PSA PSMA	1.02	0.75	1.08	0.32
pT stage	2.37	0.16	4.20	0.07
pL stage	0.76	0.34	0.92	0.80
Seminal vesicle invasion	0.48	0.45	0.48	0.49
Surgical margins	2.32	0.17	1.97	0.29
Gleason score	0.90	0.86	0.95	0.94
Time after RP	1.01	0.39	1.01	0.12

OR, odds ratio; PSMA, prostate-specific membrane antigen; RP, radical prostatectomy.

been given to focused treatment to a higher dose, using the ⁶⁸Ga-PSMA fused with the planning CT to allow a simultaneous integrated boost or ‘dose painting’.

There was a major management impact in 20 patients (28.6%) directly attributable to their ⁶⁸Ga-PSMA findings. In total, five patients (25%) had management changes which included enlarging the volume of salvage RT to include pelvic nodes and to consider the addition of adjuvant androgen deprivation therapy (ADT). One patient (5%) underwent a surgical salvage lymph node dissection (omitting salvage RT altogether), six patients (30%) were treated with salvage RT to the pelvic lymph nodes alone plus adjuvant ADT (potentially

sparing the toxicity of salvage RT to the fossa), four patients (20%) were treated with stereotactic RT of a solitary equivocal probably positive pelvic lymph node alone (all patients had negative surgical margins and \leq pT3a disease), three patients (15%) were treated with stereotactic radiotherapy for a lesion outside the pelvis with or without ADT and one patient (5%) underwent salvage RT to the prostatic fossa plus stereotactic radiotherapy for an extrapelvic lesion.

Discussion

The present study confirms results from recently published studies that ⁶⁸Ga-PSMA PET/CT is a valuable diagnostic tool in the setting of BCR after RP [15,16]. The detection rate of ⁶⁸Ga-PSMA PET/CT for recurrent PCa increased in parallel with rises in PSA values. In total, 54% of patients, with PSA values in the range of 0.2–0.5 ng/mL, had a definitely positive lesion. Until now, the onset of PSA increase often occurred long before recurrent disease could be localized clinically or by imaging. Nomograms have been established for predicting the likelihood of local recurrence or metastatic disease, resulting in high rates of overtreatment, i.e. localized salvage RT in patients with systemic disease [13]. The results of the present study show that ⁶⁸Ga-PSMA promises to differentiate local, regional and distant metastatic disease in recurrent PCa in patients with low PSA values, with considerable implications for disease management. Furthermore, in patients with BCR after RP, it showed that a high percentage of disease recurrence appears to be located beyond the prostatic fossa, and thus outside the standard salvage RT field. These findings are consistent with previous series using lymphotropic nanoparticle-enhanced MRI for the assessment of normal and abnormal lymph nodes in patients with PCa [18].

The present study showed that 58% of men with a PSA 0.2–0.29 ng/mL had pathological uptake on their ⁶⁸Ga-PSMA scan. Normally, this is the PSA level where patients are considered for salvage RT, giving them potential benefit from early salvage treatment [10,19]. Considering both the present and previous findings [16], it is likely that ⁶⁸Ga-PSMA will replace other imaging techniques for staging of BCR after RP, and may alter the treatment in men currently considered for salvage prostatic fossa radiotherapy. This highlights the main purpose of the present study, i.e. to show the clinical impact of ⁶⁸Ga-PSMA in contemporary practice. It underlines the need for additional treatment guidelines and well-designed clinical trials to determine the outcomes in terms of BCR, mortality and morbidity of treatment changes directly attributable to ⁶⁸Ga-PSMA PET/CT.

One of the main concerns in the management of PCa is the impact of a scan that is not yet well evaluated. We reported a major management change in 35% of patients based on ⁶⁸Ga-PSMA results, in most of the cases without histopathological

confirmation. The exact sensitivity and specificity of ⁶⁸Ga-PSMA, for different SUVmax values, is still to be established, although the specificity and positive predictive value appears to be very high [15,16,20]. Only limited data on ⁶⁸Ga-PSMA are available, with all larger series based on retrospective designs [20,21]. Nonetheless, the present results are consistent with the larger retrospective studies, reporting on 332 consecutive patients with BCR after RP, and presenting detection rates for ⁶⁸Ga-PSMA of 92% for PSA values 1–2 ng/mL, 72% for 0.5–1 ng/mL and 53% for PSA values 0.2–0.5 ng/mL [22]. Recently, in a retrospective analysis of the value of ⁶⁸Ga-PSMA for the preoperative staging of primary PCa, Maurer et al. [23] showed a specificity of 99%, a positive predictive value of 87%, and a sensitivity and negative predictive value of 73% and 97%, respectively, for the detection of lymph node metastases. Budäus et al. [20] presented an overall sensitivity, specificity, positive predictive value and negative predictive value of 33.3%, 100%, 100% and 69.2% in 30 patients using ⁶⁸Ga-PSMA for the preoperatively identifying lymph node metastases. In the present study, the median size of undetected lymph node metastases was 4.3 mm [20]. In other words, given its high specificity and ability to reliably demonstrate the dominant nodule, ⁶⁸Ga-PSMA might be used to delineate dominant nodule boost with salvage RT in future; however, because of its poor sensitivity, ⁶⁸Ga-PSMA PET/CT can underestimate the extent of disease, which might not justify the changes in treatment plans as presented in this study. Further research is therefore warranted.

It is clear that ⁶⁸Ga-PSMA enables the detection of PCa recurrence that would otherwise remain undetected. These results suggest that, in a significant percentage of patients with rising PSA levels, salvage RT to the prostatic fossa according to the FROGG consensus guideline would lead to geographic miss and subsequent treatment failure. These findings support the relatively high rate of patients in the study by Stephenson et al. [10] that were reported to have failed early despite salvage prostatic fossa radiotherapy; therefore, ⁶⁸Ga-PSMA will have implications for future research and the role of salvage RT, with potentially higher rates of cure after salvage RT as a result of improved patient selection or by altering the target volume to include the pelvic lymphatics as well as the prostatic fossa. This may, however, lead to an increase in toxicity. Another option might be to use ⁶⁸Ga-PSMA for detection and treatment planning by fusing the ⁶⁸Ga-PSMA with the planning CT to allow ‘dose sculpting’, which involves delivering a higher dose to the macroscopic disease. This would allow a more personalized approach, which may also decrease the salvage RT related toxicity.

In 44% of the patients, ⁶⁸Ga-PSMA was assessed to be negative, despite BCR being determined. This could be attributable to underestimation of disease in the prostate bed, an area that is frequently obscured because of tracer excretion in the bladder. Certainly, studies of multiparametric MRI in

the same patient population show higher levels of disease recurrence in the recto-prostatic fossa and at the vesico-urethral anastomosis than identified in the present study. Furthermore, this could be attributable to underestimation of disease in pelvic lymph nodes, reflected in the poor sensitivity reported by Budáus et al. [20]. The use of PET/MRI may help to overcome this potential limited sensitivity for disease recurrence with ^{68}Ga -PSMA PET/CT. Furthermore, new fluorine (F-18)-labelled compounds, such as ^{18}F -DCFPyL (2-(3-{1-carboxy-5-[(6- ^{18}F]fluoro-pyridine-3-carbonyl)-amino]-pentyl}-ureido)-pentanedioic acid), a new PSMA-selective ligand with a high binding affinity for PSMA, might be able to improve the sensitivity [24].

Salvage RT seems to be more effective when delivered at low PSA levels after BCR [8,10]. King et al. [8] presented level 2A evidence for initiating salvage RT at the lowest possible PSA value, with an average 2.6% loss of recurrence-free survival for each incremental 0.1 ng/mL PSA increase at the time of the salvage RT. Consequently, this might interfere with the optimum value of ^{68}Ga -PSMA PET/CT, with only 17% of patients in the present study presenting with a definitely ^{68}Ga -PSMA positive lesion. In other words, the additional value of ^{68}Ga -PSMA PET/CT in combination with 'late' salvage RT (PSA >0.2 ng/mL) vs 'early' salvage RT (PSA <0.2 ng/mL) has to be determined as well.

The present study has several limitations. Firstly, in almost all patients, largely because of the small size and anatomical location of subcentimetre lymph nodes, histological examination could not be obtained. Secondly, the study includes a small sample size and thereby a relatively low statistical power; however, the study purpose is to generate a hypothesis rather than to define recommendations in this treatment group, and well-designed, prospective studies are clearly required to address the questions raised by these findings. Finally, no data on PSA kinetics were included.

In conclusion, we established the value of ^{68}Ga -PSMA PET/CT for the detection of PCa recurrence in men with low serum PSA levels considered for salvage RT after RP. The impact of ^{68}Ga -PSMA findings on patient management are considerable. In our opinion, this underlines the need for further clinical trials that establish the sensitivity and specificity of ^{68}Ga -PSMA, and assess the outcomes of treatment changes in salvage therapy attributable to ^{68}Ga -PSMA. Nevertheless, ^{68}Ga -PSMA PET/CT has the potential to become a promising tool for individualized salvage treatment in patients with recurrent PCa.

Acknowledgments

We thank Ms Anne-Maree Haynes, Clinical Data Manager, Australian Prostate Cancer Research Centre NSW. This research was funded by the Australian Department of Health and Ageing for its funding of the Australian Prostate Cancer

Research Centre NSW, and the St Vincent's Prostate Cancer Centre.

Conflicts of Interest

None declared.

References

- 1 Cary KC, Punnen S, Odisho AY et al. Nationally representative trends and geographic variation in treatment of localized prostate cancer: the Urologic Diseases in America project. *Prostate Cancer Prostatic Dis* 2015; 18: 149–54
- 2 Han M, Partin AW, Pound CR, Epstein JI, Walsh PC. Long-term biochemical disease-free and cancer-specific survival following anatomic radical retropubic prostatectomy. The 15-year Johns Hopkins experience. *Urol Clin North Am* 2001; 28: 555–65
- 3 Liauw SL, Pitroda SP, Eggenner SE et al. Evaluation of the prostate bed for local recurrence after radical prostatectomy using endorectal magnetic resonance imaging. *Int J Radiat Oncol Biol Phys* 2013; 1: 378–84
- 4 Beresford MJ, Gillatt D, Benson RJ, Ajithkumar T. A systematic review of the role of imaging before salvage radiotherapy for post-prostatectomy biochemical recurrence. *Clin Oncol* 2010; 22: 46–55
- 5 Picchio M, Briganti A, Fanti S et al. The role of choline positron emission tomography/computed tomography in the management of patients with prostate-specific antigen progression after radical treatment of prostate cancer. *Eur Urol* 2011; 59: 51–60
- 6 Sidhom MA, Kneebone AB, Lehman M et al. Post-prostatectomy radiation therapy: consensus guidelines of the Australian and New Zealand Radiation Oncology Genito-Urinary Group. *Radiother Oncol* 2008; 88: 10–9
- 7 Heidenreich A, Bastian PJ, Bellmunt J et al. EAU guidelines on prostate cancer. Part II: Treatment of advanced, relapsing, and castration-resistant prostate cancer. *Eur Urol* 2014; 65: 467–79
- 8 King CR. The timing of salvage radiotherapy after radical prostatectomy: a systematic review. *Int J Radiat Oncol Biol Phys* 2012; 1: 104–11
- 9 Pfister D, Bolla M, Briganti A et al. Early salvage radiotherapy following radical prostatectomy. *Eur Urol* 2014; 65: 1034–43
- 10 Stephenson AJ, Scardino PT, Kattan MW et al. Predicting the outcome of salvage radiation therapy for recurrent prostate cancer after radical prostatectomy. *J Clin Oncol* 2007; 20: 2035–41
- 11 Choo R, Hruby G, Hong J et al. (IN)-efficacy of salvage radiotherapy for rising PSA or clinically isolated local recurrence after radical prostatectomy. *Int J Radiat Oncol Biol Phys* 2002; 1: 269–76
- 12 Boorjian SA, Thompson RH, Tollefson MK et al. Long-term risk of clinical progression after biochemical recurrence following radical prostatectomy: the impact of time from surgery to recurrence. *Eur Urol* 2011; 59: 893–9
- 13 Briganti A, Karnes RJ, Joniau S et al. Prediction of outcome following early salvage radiotherapy among patients with biochemical recurrence after radical prostatectomy. *Eur Urol* 2014; 66: 479–86
- 14 Sweat SD, Pacelli A, Murphy GP, Bostwick DG. Prostate-specific membrane antigen expression is greatest in prostate adenocarcinoma and lymph node metastases. *Urology* 1998; 52: 637–40
- 15 Afshar-Oromieh A, Zechmann CM, Malcher A et al. Comparison of PET imaging with a (68)Ga-labelled PSMA ligand and (18)F-choline-based PET/CT for the diagnosis of recurrent prostate cancer. *Eur J Nucl Med Mol Imaging* 2014; 41: 11–20
- 16 Morigi JJ, Stricker PD, van Leeuwen PJ et al. Prospective comparison of ^{18}F -fluoromethylcholine versus ^{68}Ga -PSMA PET/CT in prostate cancer patients who have rising PSA after curative treatment and are being considered for targeted therapy. *J Nucl Med* 2015; 56: 1185–90

- 17 Mannweiler S, Amersdorfer P, Trajanoski S, Terrett JA, King D, Mehes G. Heterogeneity of prostate-specific membrane antigen (PSMA) expression in prostate carcinoma with distant metastasis. *Pathol Oncol Res* 2009; 15: 167–72
- 18 Harisinghani MG, Barentsz J, Hahn PF et al. Noninvasive detection of clinically occult lymph-node metastases in prostate cancer. *N Engl J Med* 2003; 348: 2491–9
- 19 Lehman M, Sidhom M, Kneebone AB et al. FROGG high-risk prostate cancer workshop: patterns of practice and literature review. Part II post-radical prostatectomy. *J Med Imaging Radiat Oncol* 2014; 58: 392–400
- 20 Budaus L, Leyh-Bannurah SR, Salomon G et al. Initial experience of Ga-PSMA PET/CT imaging in high-risk prostate cancer patients prior to radical prostatectomy. *Eur Urol* 2015; 24: 513–8
- 21 Afshar-Oromieh A, Haberkorn U, Hadaschik B et al. PET/MRI with a ⁶⁸Ga-PSMA ligand for the detection of prostate cancer. *Eur J Nucl Med Mol Imaging* 2013; 40: 1629–30
- 22 Maurer TGJW, Souvatzoglou H, Beer M et al. PET imaging with ⁶⁸Gallium-labelled ligand of prostate-specific membrane antigen (⁶⁸Ga-HBED-PSMA) for staging of biochemical recurrent prostate cancer after radical prostatectomy. *J Clin Oncol* 2015; (abstract e5023)
- 23 Maurer TGJW, Souvatzoglou H, Beer M et al. PET imaging with of prostate-specific membrane antigen (PSMA) for staging of primary prostate cancer with ⁶⁸Ga-HBED-PSMA. *J Clin Oncol* 2015; (abstract e16038)
- 24 Dietlein M, Kobe C, Kuhnert G et al. Comparison of [(18)F]DCFPyL and [(68)Ga]Ga-PSMA-HBED-CC for PSMA-PET Imaging in Patients with Relapsed Prostate Cancer. *Mol Imaging Biol* 2015; 17: 575–84

Correspondence: Pim J. van Leeuwen, Level 6, The Kinghorn Cancer Centre, 370 Victoria Street, Darlinghurst, NSW 2010, Australia.

e-mail: p.vanleeuwen@garvan.org.au

Abbreviations: PET, positron emission tomography; BCR, biochemical recurrence; RP, radical prostatectomy; PCa, prostate cancer; RT, radiation therapy; PSMA, prostate-specific membrane antigen; SUVmax, maximum standardized uptake value; FROGG, the Faculty of Radiation Oncology Genito-Urinary Group; ADT, androgen deprivation therapy.

Supporting Information

Additional Supporting Information may be found in the online version of this article:

Appendix 1 ⁶⁸Ga-PSMA Imaging Reporting Form ProCan-I database site codes